

NRC Publications Archive Archives des publications du CNRC

A randomized comparison between neurostimulation and ultrasound-guided lateral femoral cutaneous nerve block

Gupta, Gaurav; Radhakrishna, Mohan; Tamblyn, I.; Tran, De QH;
Besemann, Markus; Thonnagith, Atikun; Elgueta, Maria Francisca;
Robitaille, Marie Eve; Finlayson, Roderick J.

This publication could be one of several versions: author's original, accepted manuscript or the publisher's version. /
La version de cette publication peut être l'une des suivantes : la version prépublication de l'auteur, la version
acceptée du manuscrit ou la version de l'éditeur.

Publisher's version / Version de l'éditeur:

U.S. Army Medical Department Journal, 2017, July-Sept., pp. 33-38, 2017-09-01

NRC Publications Archive Record / Notice des Archives des publications du CNRC :

<https://nrc-publications.canada.ca/eng/view/object/?id=a881526e-18f1-4a3d-a2fd-057fb2f364e1>

<https://publications-cnrc.canada.ca/fra/voir/objet/?id=a881526e-18f1-4a3d-a2fd-057fb2f364e1>

Access and use of this website and the material on it are subject to the Terms and Conditions set forth at

<https://nrc-publications.canada.ca/eng/copyright>

READ THESE TERMS AND CONDITIONS CAREFULLY BEFORE USING THIS WEBSITE.

L'accès à ce site Web et l'utilisation de son contenu sont assujettis aux conditions présentées dans le site

<https://publications-cnrc.canada.ca/fra/droits>

LISEZ CES CONDITIONS ATTENTIVEMENT AVANT D'UTILISER CE SITE WEB.

Questions? Contact the NRC Publications Archive team at

PublicationsArchive-ArchivesPublications@nrc-cnrc.gc.ca. If you wish to email the authors directly, please see the first page of the publication for their contact information.

Vous avez des questions? Nous pouvons vous aider. Pour communiquer directement avec un auteur, consultez la première page de la revue dans laquelle son article a été publié afin de trouver ses coordonnées. Si vous n'arrivez pas à les repérer, communiquez avec nous à PublicationsArchive-ArchivesPublications@nrc-cnrc.gc.ca.

A Randomized Comparison Between Neurostimulation and Ultrasound-Guided Lateral Femoral Cutaneous Nerve Block

Gaurav Gupta, MD, FRCPC
Mohan Radhakrishna, MD, FRCPC
Isaac Tamblyn, PhD
De QH Tran, MD, FRCPC
LCol Markus Besemann, MD, FRCPC

Atikun Thonnagith, MD
Maria Francisca Elgueta, MD
MCpl Marie Eve Robitaille, AEC
Roderick J Finlayson, MD, FRCPC

ABSTRACT

Background: This prospective, randomized trial compared neurostimulation (NS) and ultrasound (US) guided lateral femoral cutaneous nerve (LFCN) block. We hypothesized that US would result in a shorter total anesthesia-related time (sum of performance and onset times).

Methods: Twenty-one volunteers were enrolled. The right lower limb was randomized to an NS- or US-guided LFCN block. The alternate technique was employed for the left lower limb. With NS, paresthesias were sought in the lateral thigh at a stimulatory threshold of 0.6 mA (pulse width=0.3 ms; frequency=2 Hz) or lower. With US, local anesthetic was deposited under the inguinal ligament, ventral to the iliopsoas muscle. In both groups, 5 mL of lidocaine 2% were used to anesthetize the nerve. During the procedure of the block, the performance time and number of needle passes were recorded. Subsequently, a blinded observer assessed sensory block in the lateral thigh every minute until 20 minutes. Success was defined as loss of pinprick sensation at a point midway between the anterior superior iliac spine and the lateral knee line. The blinded observer also assessed the areas of sensory block in the anterior, medial, lateral, and posterior aspects of the thigh and mapped this distribution onto a corresponding grid.

Results: Both modalities provided comparable success rates (76.2%-95.2%), performance times (162.1 to 231.3 seconds), onset times (300.0 to 307.5 seconds) and total anesthesia related-times (480.1 to 554.0 seconds). However US required fewer needle passes (3.2 ± 2.9 vs 9.5 ± 12.2 ; $P=.009$). There were no intergroup differences in terms of the distribution of the anesthetized cutaneous areas. However considerable variability was encountered between individuals and between the 2 sides of a same subject. The most common areas of sensory loss included the central lateral two-eighths anteriorly and the central antero-inferior three-eighths laterally.

Conclusion: Ultrasound guidance and NS provide similar success rates and total anesthesia-related times for LFCN block. The territory of the LFCN displays wide inter- and intra-individual variability.

Meralgia paresthetica, a painful mononeuropathy of the lateral femoral cutaneous nerve (LFCN), can result from injury, compression or mechanical irritation of the latter.¹ Lateral femoral cutaneous nerve block plays an instrumental role in the diagnosis and management of meralgia paresthetica.¹ Techniques for LFCN block include blind infiltration, neurostimulation (NS), and ultrasound (US)-guidance.²⁻⁴ In a randomized crossover study, blind infiltration was compared to NS.² The latter resulted in a greater success rate (100% vs 40%; $P<.001$) coupled with a shorter onset time ($P<.02$).² Although several recent reports³⁻⁴ have advocated US for LFCN block, to date, no RCT has compared NS- and US-guided techniques.

In this randomized, volunteer study, we set out to compare NS- and US-guided LFCN blocks. We hypothesized

that US would provide shorter performance and onset times. Thus, the primary outcome was the total anesthesia-related time (ie, the sum of performance and onset times). We also aimed to describe the triplanar sensory distribution of the LFCN after local anesthetic blocks.

MATERIAL AND METHODS

The current trial was registered at Clinicaltrials.gov (Identifier: NCT02577510) on October 14, 2015. After obtaining ethics committee approval (Defence Research and Development Canada Human Research Ethics Committee) and written informed consent, we enrolled 21 volunteers. Inclusion criteria were age between 18 and 60 years, American Society of Anesthesiologists (ASA) physical status I to II, and body mass index between 20 kg/m² and 40 kg/m². Exclusion criteria included

A RANDOMIZED COMPARISON BETWEEN NEUROSTIMULATION- AND ULTRASOUND-GUIDED LATERAL FEMORAL CUTANEOUS NERVE BLOCK

coagulopathy, pregnancy, breast feeding, hepatic or renal failure, allergy to local anesthetic (LA), prior surgery in the inguinal area, and neuropathy impacting sensation of the lateral thigh.

All LFCN blocks were performed by 2 operators (authors G. G. and R. J. F.) experienced with the NS and US techniques. They were carried out in a medical facility with access to resuscitative equipment and drugs. Volunteers were positioned supine. Using a computer-generated sequence of random numbers and a sealed envelope technique, the right lower limb was randomized to an NS- or US -guided LFCN block. The alternate technique was employed for the left lower limb.

The NS technique was modified from the earlier description of Shannon et al.² After disinfection and draping, a skin wheal (using 0.5 mL of lidocaine 1%) was raised 2 cm medial to the anterior superior iliac spine (ASIS) and 1 cm caudal to the inguinal ligament (Figure 1). A 22-gauge block needle (SonoPlex Stimcannula, Pajunk Mediztechnologie, Geisingen, Germany) attached to a nerve stimulator (MultiStimSwitch, Pajunk Mediztechnologie, Geisingen, Germany) set at a current of 1.5 mA (pulse width=0.3 ms; frequency=2 Hz) was then inserted. Paresthesias were sought along the lateral aspect of the thigh. If sensory stimulation was not found with the initial insertion, the needle was advanced superficially in a fan-like pattern towards the ASIS. After confirming the presence of paresthesia at a threshold of 0.6 mA or lower, 5 mL of lidocaine 2% were injected to anesthetize the LFCN.

The US technique was performed according to the description of Hara et al.⁵ After skin disinfection and draping, a 6-13 MHz linear US probe (probe SL3323,




Figure 1. Needle in position for a block of the lateral femoral cutaneous nerve using the nerve stimulation technique. A line has been drawn (B) between the anterior superior iliac spine (ASIS) and the pubic tubercle. The skin puncture site is 2 cm medial along this line and 1 cm caudal to it.

MyLabTouch, Esoate, Genova, Italy) was applied in a sterile fashion medially to the ASIS and caudally to the inguinal ligament, in order to obtain a short axis view of the iliopsoas muscle. A skin wheal was raised with 0.5 mL of lidocaine 1%. Using an out-of-plane technique, a 22-gauge block needle was advanced until its tip was positioned just ventral to the iliopsoas muscle. Five mL of lidocaine 2% were deposited in this location (Figure 2).

For the US group, the imaging time was defined as the time interval between contact of the US probe with the patient and the acquisition of a satisfactory picture. For both groups, the performance time was defined as the temporal interval between the start of the procedure (skin-probe contact for the US group and skin wheal for the NS group) and the end of LA injection through the block needle. Imaging and performance times were

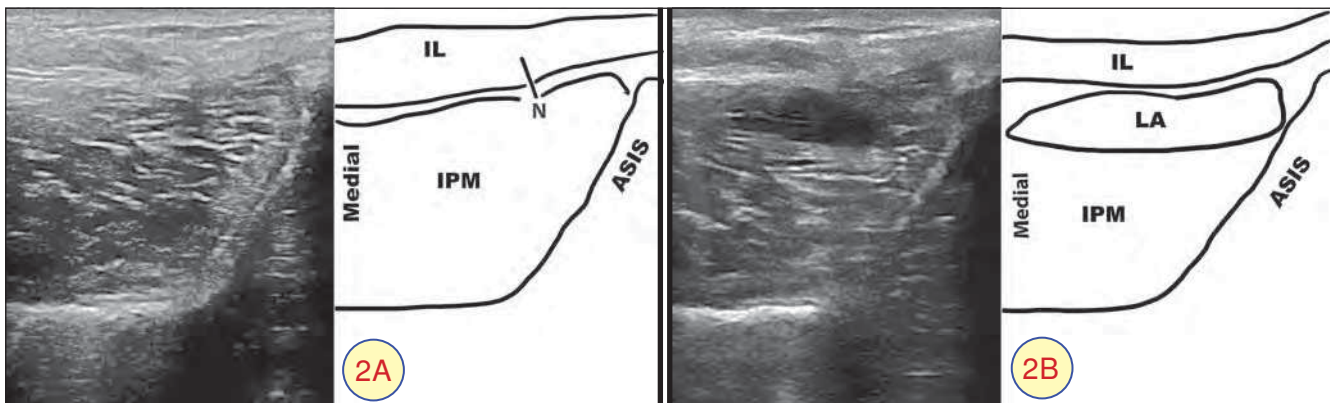


Figure 2. Ultrasound guided block of the lateral femoral cutaneous nerve.

2A: an out-of-plane needle (N) has been placed through the inguinal ligament (IL), ventral to the iliopsoas muscle (IPM), one centimeter medial to the anterior superior iliac spine (ASIS).

2B: 5 mL of local anesthetic (LA) has been injected, spreading under the inguinal ligament (IL) and ventral to the iliopsoas muscle (IPM).

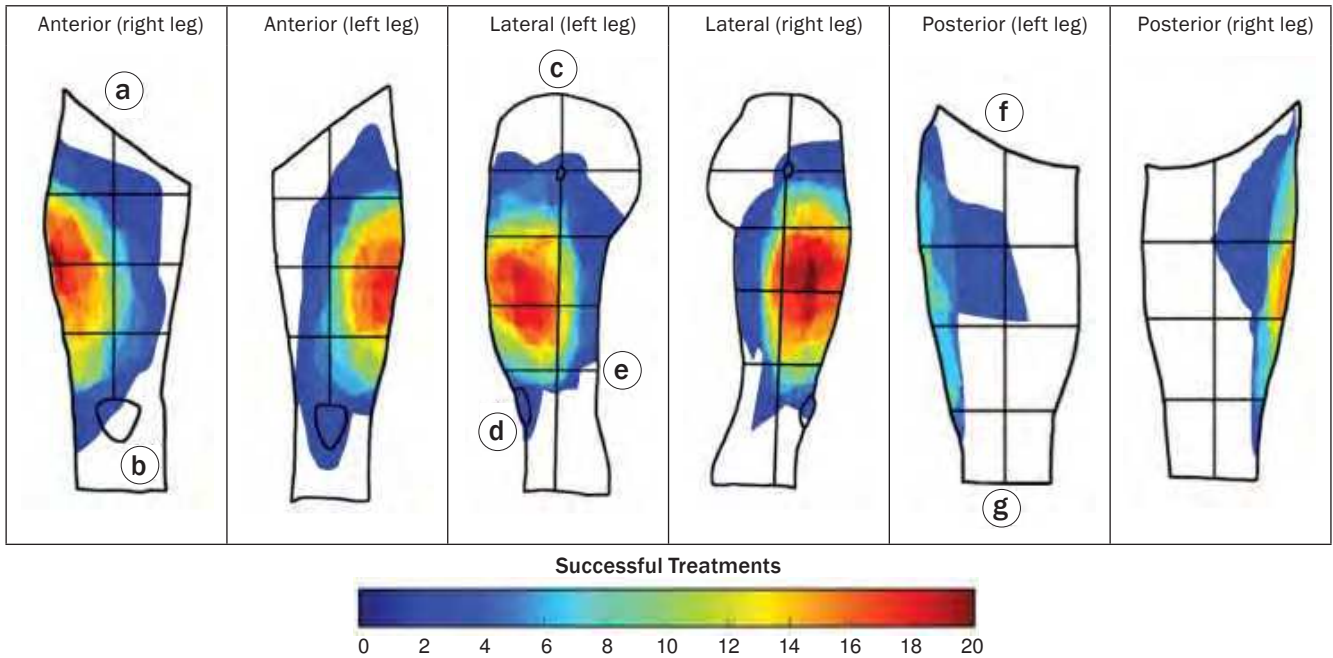


Figure 3A. Sensory area distribution maps observed for successful nerve blocks. Overlapping areas shared between patients are denoted by the area color.

Legend: a. Anterior superior Iliac spine d. Patella (lateral view) g. Popliteal crease
 b. Patella (anterior view) e. Lateral joint line
 c. Greater trochanter f. Gluteal fold

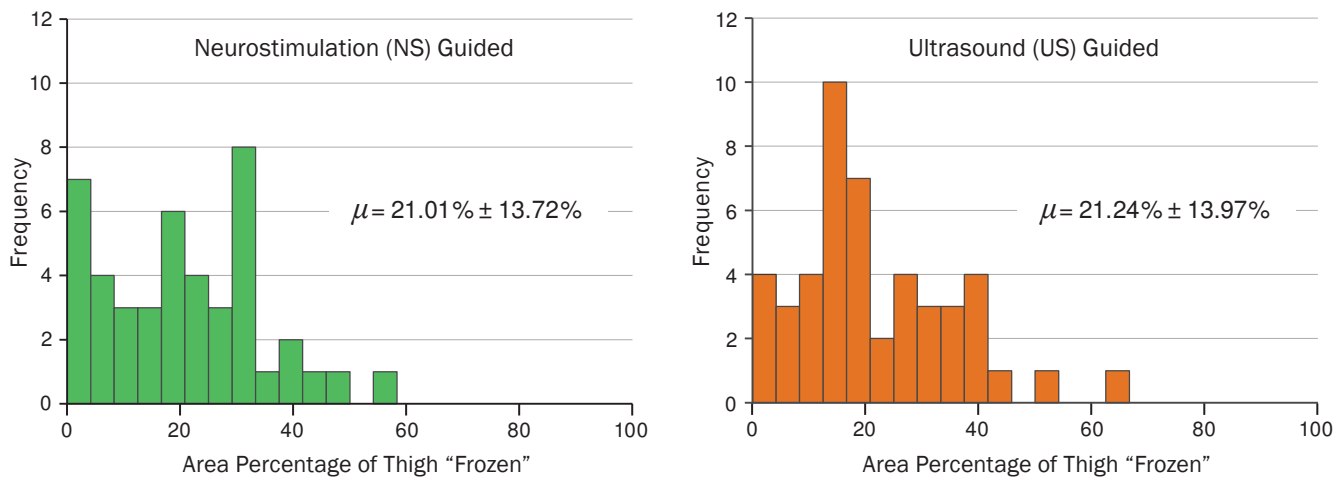


Figure 3B. Histogram of frozen areas (reported as a percentage of patient thigh surface area) experienced by patients for successful NS and US treatments. Average freeze area percentage for each treatment protocol are shown.

recorded by the (nonblinded) investigator assisting the primary operator. The number of needle passes was also recorded by the nonblinded assistant. The initial needle insertion counted as the first pass. Any subsequent needle advancement that was preceded by a retraction of at least 10 mm counted as an additional pass.⁶

minutes by a blinded observer. Block success was defined as loss of sensation to pinprick at a point midway between the ASIS and the lateral knee line.² Onset time was defined as the temporal interval required to achieve success. Thus total anesthesia-related time equaled the sum of performance and onset times.

After LA injection through the block needle, LFCN block was tested over the lateral aspect of the thigh. Measurements were carried out every minute until 20

In addition to recording anthropometric data, the blinded observer also assessed incidental femoral block (knee extension) at 20 minutes and procedural pain using a

A RANDOMIZED COMPARISON BETWEEN NEUROSTIMULATION- AND ULTRASOUND-GUIDED LATERAL FEMORAL CUTANEOUS NERVE BLOCK

visual analog scale (0 cm indicates no pain; 10 cm indicates worst imaginable pain).

For those patients with successful LFCN blocks at 20 minutes, the blinded assessor proceeded to determine the extent of the sensory loss in all directions from the reference point. A mark was made where sensation was deemed to have normalized, and the distribution was transferred to the respective grid (Figure 3). Using washable markers, the grids were premarked into quartiles (based on length) in all views, and then further subdivided into eighths. Anteriorly, quartiles were calculated by dividing the distance from the ASIS to superior patella into equal fourths, and then further subdivided into eighths with a bisecting line drawn superiorly from the midpoint of the patella. Laterally, the distance from the superior edge of the greater trochanter to the lateral joint line of the knee was divided into quartiles, and then further subdivided into eighths with a bisecting line drawn superiorly from the midpoint of the lateral joint line. Posteriorly, the distance between the gluteal and popliteal folds was divided into fourths, and then further subdivided into eighths with a bisecting line drawn superiorly from the midpoint of the popliteal fossa.

STATISTICAL ANALYSIS

We expected similar success rates for both groups. Our research hypothesis was that performance and onset times would be different. Therefore, the main outcome was the total anesthesia-related time (sum of performance and onset times). According to Shannon et al,² the total anesthesia-related time with NS is 10.1±4.7 minutes. Using a paired *t* test to compare both techniques, a 30% difference in total time represented an effect size of 0.74 and required a total of 17 subjects undergoing bilateral blocks in order to achieve a 2-tailed α error of 0.05 and a β error of 0.2. Since onset and total anesthesia-related times can only be calculated for successful blocks, and since we expected an 85% success rate with NS, 20 subjects were needed to account for block failure. Because 21 volunteers inquired about study participation, we decided to enroll all 21 subjects.

Statistical analysis was performed using SPSS Version 21 statistical software (IBM, Armonk, New York). For continuous data, normality was first assessed with the Lilliefors test and then analyzed using a paired *t* test. Data that did not have a normal distribution, as well as ordinal data, was analyzed using Wilcoxon's signed ranks or McNemar's test. All *P*

values presented were 2-sided and values inferior to .05 were considered significant.

For territorial mapping of the LFCN, initial digitization was handled with a digital scanner. We used a combination of guided curve detection (as implemented in GraphClick (Arizona-Software.ch, Neuchatel, Switzerland)) and our own implementation of the flood fill algorithm to segment images between FROZEN and UN-FROZEN. All images were area-normalized, allowing for comparison between subjects of different physical sizes. Subsequently, images were aligned within \pm one degree. Treatment heat-maps (Figure 3) were generated using Matplotlib (<http://matplotlib.org>). Statistics for the sensor distribution were computed using the open source python module SciPy (<http://scipy.org>).

RESULTS

All LFCN blocks were performed over a period of 2 days (November 7-8, 2015).

Demographic data are presented in Table 1. Both techniques provided similar success rates (76.2%-95.2%), performance times (162.1-231.3 seconds), onset times (300.0-307.5 seconds), total anesthesia related-times (480.1-554.0 seconds) and procedural pain scores (4.0-4.6). However US required fewer needle passes (3.2±2.9 vs 9.5±12.2; *P*=.009) (Table 2). At 20 minutes, one volunteer (US group) displayed incidental femoral nerve blockade.

No statistical differences were detected when comparing the distribution of sensory loss between US and NS-guided LFCN blocks. The overall average surface area coverage was similar, with normative distribution observed in the available sample size. However considerable variability was encountered between individuals

Age (years)	40.3 (10.0)
Sex (male/female)	17/4
Body mass index	26.7 (3.5)
Continuous variables are presented as means (SD). Categorical variables are presented as count.	

	Ultrasound (N=21)	Nerve Stimulation (N=21)	<i>P</i> value
Imaging time	22.5 (19.6)	NA	NA
Performance time	162.1 (125.8)	231.3 (210.9)	.138
Onset time	307.5 (157.8)	300.0 (236.0)	.920
Total anesthesia-related time	480.1 (251.9)	554.0 (366.9)	.443
Success rate (%)	20.0 (95.2)	16.0 (76.2)	.125
Number of passes	3.2 (2.9)	9.5 (12.2)	.009
Block-related pain (VAS score)	4.6 (2.2)	4.0 (2.2)	.139
Incidental femoral block	1.0 (4.8)	0 (0)	>.999
All time variables are in seconds. Continuous variables are presented as means (SD). Categorical variables are presented as count (percentage). NA indicates not applicable; VAS, visual analog scale.			

and between the 2 sides of a same subject (Figure 3). The most common areas of sensory loss included the central lateral two-eighths anteriorly and the central antero-inferior three-eighths laterally.

COMMENT

In this randomized trial, we compared NS- and US-guided LFCN blocks. Our results reveal that both modalities result in similar success rates and total anesthesia-related times. We speculate that the lack of intergroup differences stem from the superficial position of the LFCN. Although US confers significant advantages for brachial plexus, femoral, and sciatic nerve blocks,⁷⁻⁸ its benefits may not extend to smaller neural structures. For instance, Tran et al⁹ reported comparable success rates (80%-85%) and onset times for US and landmark-guided superficial cervical plexus blocks. Similarly, Fredrickson et al¹⁰ found no differences in success rate (80%-89%) for ankle blocks performed with the conventional infiltrative method (using 30 mL of ropivacaine 0.5%) or US. Furthermore, in 18 volunteers randomized to a landmark-based deep peroneal nerve block on one side and a US technique on the other, Antonakakis et al¹¹ observed similar sensory and motor block between 20 and 60 minutes.

We attribute our 76.2%-95.2% success rates to anatomical variations of the LFCN. Instead of being a singular structure, the latter can divide into multiple branches proximal to the inguinal ligament in 28% of cases.¹² For these subjects, NS would provide limited success as paresthesias may only reflect needle tip proximity with an end branch and not the parent trunk. Furthermore the LFCN can be found dorsal, ventral, or lateral to the ASIS.¹³⁻¹⁵ In the event that the nerve is ventral to the latter, subinguinal LA deposition (with US guidance) would result in failure.

The technique employed in our US group requires discussion. In the literature, most descriptions pertaining to US guidance have painstakingly identified the LFCN prior to targeting it with LA. In contrast, Hara et al⁵ simply used US to inject LA under the inguinal ligament, ventral to the iliopsoas muscle. In 2011, these authors compared their subinguinal method to a nerve-targeting US technique. A significantly higher success rate was achieved with the former (95.9% vs 74.5%; $P=.0027$).⁵ Thus, in the current trial, we opted for the subinguinal technique because it represents the best evidence-based option available. Similarly, for the control group, we purposefully selected NS instead of blind LA infiltration.²

The interindividual variability in the sensory distribution of the LFCN has been previously described. Corujo

et al¹⁶ reported that in 40.9% of patients, the LFCN displayed a “typical” territory (lateral thigh without extension past the midline of the anterior thigh). However, in 45.5% of the subjects, the sensory distribution of the LFCN encompassed both lateral and anterior aspects of the thigh. Conversely, in 13.6% of the subjects, it was confined to a small, circumscribed area on the lateral thigh.¹⁶ In 16 patients, Hopkins et al¹⁷ found that, after a successful LFCN block, the area of sensory loss was frequently “pear-drop shaped” with its apex lying over or distal to the greater trochanter and its body extending distally and anteriorly towards the knee. However, there existed no region of the thigh that was consistently anesthetized in all 16 subjects.¹⁷ In addition to confirming previous reports by Corujo et al¹⁶ and Hopkins et al¹⁷ pertaining to interindividual variability, our results also reveal for the first time that the sensory innervation of the LFCN can vary within the same individual between right and left lower limbs.

Our protocol contains some limitations. Firstly, our findings are specific to the 5 mL-injectate. We cannot rule out potential differences between NS and US with larger LA volumes. However larger injectates may increase the risk of incidental femoral nerve block, thereby hindering the diagnostic value of LFCN block for meralgia paresthetica. Secondly, the 4.8% rate of femoral block (US group) suggests that even volumes as small as 5 mL can result in LA migration from the LFCN to the femoral nerve. Thus dose-finding studies are required for LFCN block. Thirdly, the benefits derived from the US subinguinal technique (decreased needle passes) apply solely to LFCN blocks with LA. Neuroablative procedures, such as pulsed radiofrequency, would still require targeted identification of the LFCN (with NS or US). Finally, there exists no standard method to delineate neural sensory distribution. Any mapping technique inherently carries a certain amount of imprecision. Nonetheless, future studies could employ 3-dimensional scanning technology to determine the sensory topography for various nerves blocks.

In conclusion, US and NS provide similar success rates and total anesthesia-related times for LFCN block. The territory of the LFCN displays wide inter- and intra-individual variability: the most common distributions in the thigh encompass the central lateral two-eighths anteriorly and the central antero-inferior three-eighths laterally.

ACKNOWLEDGEMENTS

We thank Sgt Ann Dostie, Captain Alex Duong, and Dr Marco Erak for their significant contributions to the administration of this study.

A RANDOMIZED COMPARISON BETWEEN NEUROSTIMULATION- AND ULTRASOUND-GUIDED LATERAL FEMORAL CUTANEOUS NERVE BLOCK

REFERENCES

1. Hui GKM, Peng PWH. Meralgia paresthetica. What an anesthesiologist should know. *Reg Anesth Pain Med.* 2011;36:156-161.
2. Shannon J, Lang SA, Yip RW, Gerard M. Lateral femoral cutaneous nerve block revisited. A nerve stimulator technique. *Reg Anesth.* 1995;20:100-104.
3. Ng I, Vaghadia H, Choi PT, Helmy N. Ultrasound imaging accurately identifies the lateral femoral cutaneous nerve. *Anesth Analg.* 2008;107:1070-1074.
4. Hurdle MF, Weingarten TN, Crsostomo RA, Psimos C, Smith J. Ultrasound-guided blockade of the lateral femoral cutaneous nerve: technical description and review of 10 cases. *Arch Phys Med Rehabil.* 2007;88:1362-1364.
5. Hara K, Sakura S, Shido A. Ultrasound-guided lateral femoral cutaneous nerve block: comparison of two techniques. *Anaesth Intensive Care.* 2011;39:69-72.
6. Konrad C, Schupfer G, Wietlisbach M, Gerber H. Learning manual skills in Anesthesiology: is there a recommended number of cases for anesthetic procedures?. *Anesth Analg.* 1998;86:635-639.
7. Neal JM, Gerancher JC, Hebl JR, Ilfeld BM, et al. Upper extremity regional anesthesia: essentials of our current understanding, 2008. *Reg Anesth Pain Med.* 2009;34:134-170.
8. Tran DQH, Clemente A, Finlayson RJ. A review of approaches and techniques for lower extremity nerve blocks. *Can J Anesth.* 2007;54:922-934.
9. Tran DQH, Dugani S, Finlayson RJ. A randomized comparison between ultrasound-guided and landmark-based superficial cervical plexus block. *Reg Anesth Pain Med.* 2010;35:539-543.
10. Fredrickson MJ, White R, Danesh-Clough TK. Low-volume ultrasound-guided nerve block provides inferior postoperative analgesia compared to a higher-volume landmark technique. *Reg Anesth Pain Med.* 2011;36:393-398.
11. Antonakakis JG, Scalzo DC, Jorgenson AS, et al. Ultrasound does not improve the success rate of a deep peroneal nerve block at the ankle. *Reg Anesth Pain Med.* 2010;35:217-221.
12. Grothaus MC, Holt M, Mekhail AO, et al. Lateral femoral cutaneous nerve: an anatomic study. *Clin Orthop Relat Res.* 2005;437:164-168.
13. Aszmann OC, Dellon ES, Dellon AL. Anatomical course of the lateral femoral cutaneous nerve and its susceptibility to compression and injury. *Plast Reconstr Surg.* 1997;100:600-604.
14. Murata Y, Takahashi Y, Yamagata M, et al. The anatomy of the lateral femoral cutaneous nerve, with special reference to the harvesting of iliac bone graft. *J Bone Joint Surg Am.* 2000;82:746-747.
15. Kosiyatrakul A, Nuansalee N, Luenam S, Koonchornboon T, Prachaporn S. The anatomic variation of the lateral femoral cutaneous nerve in relation to the anterior superior iliac spine and the iliac crest. *Musculoskelet Surg.* 2010;94:17-20.
16. Corujo A, Franco CD, Williams JM. The sensory territory of the lateral cutaneous nerve of the thigh as determined by anatomic dissections and ultrasound-guided blocks. *Reg Anesth Pain Med.* 2012;37:561-564.
17. Hopkins PM, Ellis FR, Halsall PJ. Evaluation of local anaesthetic blockade of the lateral femoral cutaneous nerve. *Anaesth.* 1991;46:95-96.

AUTHORS

Dr Gupta, a physiatrist, works with the Canadian Forces Health Services Centre-Ottawa and the Alan Edwards Pain Management Unit of the Department of Anesthesia, Montreal General Hospital. He is also an Adjunct Professor at McGill University in Montreal, Quebec.

Dr Radhakrishna is with the Division of Physical Medicine and Rehabilitation, Department of Medicine and the Alan Edwards Pain Management Unit of the Department of Anesthesia, Montreal General Hospital. He is also an Associate Professor at McGill University in Montreal, Quebec.

Dr Tamblyn is a Research Officer with the National Research Council of Canada. He is also an Assistant Professor of Physics at the University of Ontario Institute of Technology, Oshawa, Ontario.

Dr Tran is with the Department of Anesthesia, Montreal General Hospital. He is also an Associate Professor at McGill University in Montreal, Quebec.

LCol Besemann, a physiatrist, is head of the Canadian Forces physical rehabilitation program at the Canadian Forces Health Services Group Headquarters in Ottawa. He also works at the Canadian Forces Health Services Centre and is a lecturer at the University of Ottawa.

Dr Thonnagith is a Fellow in the Department of Anesthesia, Montreal General Hospital, and now staff within the Faculty of Medicine, Chulalongkorn University, Thailand.

Dr Elgueta is a Fellow in the Department of Anesthesia, Montreal General Hospital, and affiliated with the Pontificia Universidad Catolica de Chile.

MCpl Robitaille is with the Canadian Forces Health Services Centre-Ottawa, Ontario.

Dr Finlayson is an anesthesiologist with the Alan Edwards Pain Management Unit of the Department of Anesthesia, Montreal General Hospital. He is also a Professor at McGill University in Montreal, Quebec.

Copyright of U.S. Army Medical Department Journal is the property of U.S. Army Medical Department and its content may not be copied or emailed to multiple sites or posted to a listserv without the copyright holder's express written permission. However, users may print, download, or email articles for individual use.